

Split-face comparison of fractional ablative CO₂ and fractional nonablative laser devices for skin rejuvenation

James A. Heinrich, M.D., F.A.C.S.

Pacific Coast Cosmetic & Laser Medical Center, Inc.
26730 Crown Valley Parkway, Suite 250
Mission Viejo, CA 92691

Background and Objective: Deep laser skin resurfacing is associated with prolonged downtime and healing time. Our objective was to compare the efficacy, downtime, and healing time of a fractional, ablative CO₂ and a fractional photothermolytic (FP) nonablative laser device.

Methods: Ten subjects (9 women) with visible cutaneous photodamage were randomized to receive a single treatment with a CO₂ device (UltraPulse® with ActiveFX™, Lumenis Inc.) on one side of the face and five treatments with an FP device (Fraxel SR™, Reliant Technologies) on the other side of the face. Efficacy and healing parameters were clinically and photographically evaluated before and after treatment. Collagen remodeling was assessed histologically on both sides of the face.

Results: Clinical benefits after a single treatment with the CO₂ device were equivalent to those after five treatments with the FP device. The treatment duration with the CO₂ device was 6.2 minutes compared to a mean of 24.3 minutes with the FP device, a statistically significant difference ($p = 0.0002$); the swelling after a single CO₂ treatment resolved within 4.3 days vs. a total of 13.0 days for the five FP treatments; posttreatment redness resolved in 5.3 days with the CO₂ device compared to a mean of 16.5 days (5 treatments) with the FP device; duration of posttreatment discomfort was 3.3 days with the CO₂ device compared to a mean of 6.0 days (5 treatments) with the FP device; and the downtime was 4.2 days with the CO₂ device compared to a mean of 6.5 days (5 treatments) with the FP device. Histological studies showed that collagen stimulation was 50% greater with the CO₂ device. Clinically, the investigator observed a 30% improvement in wrinkles on the CO₂-treated side and a 10% to 15% improvement on the side treated with the FP device.

Conclusion: The efficacy and safety associated with fractional, ablative CO₂ laser treatment (ActiveFX™) appears to be superior to that of the nonablative FP device (Fraxel SR™).

INTRODUCTION

Laser skin resurfacing is considered the gold standard treatment of rhytids and photodamaged skin.¹ The major disadvantage of this approach is prolonged healing time. Treatment modalities designed to both reduce healing time and yet obtain reasonably good results have recently become available. The ActiveFX procedure of the UltraPulse Encore (Lumenis, Inc., Yokneam, Israel) device uses less aggressive treatment parameters than traditional CO₂ laser devices. This study is designed to compare subject downtime and clinical improvement in photodamaged skin after a single ActiveFX treatment with the UltraPulse® Encore™ laser, and after multiple treatments with a fractional photothermolytic (FP) device (Fraxel SR, Reliant Technologies, Mountain View, CA).

The UltraPulse® Encore™ is a 10.6-micron CO₂ laser device designed to target water. The ActiveFX mode is a subset of the UltraPulse® Encore™ that requires the CPG handpiece to perform fractional

skin resurfacing. ActiveFX ablates only the epidermal layer of the skin, leaving intact healthy bridges of skin which results in immediate re-epithelialization. When bridges of healthy tissue are left intact, the healing time after this procedure is significantly reduced. The result is thermal coagulation and fractional ablation with minimal downtime. The ActiveFX parameters are energy levels of 70 to 100 mJ (55-80 µm depth) with density levels from 1 to 3 (55%-95% of ablation and thermal heating zones).

The Fraxel® SR Laser System is a 1540-nm glass fiber laser that produces subablative pulses of light ranging from 6 to 20 mJ. The Fraxel SR™ device uses optics to deliver a pattern of thermal energy to the epidermis and upper dermis.² The device creates a pattern of microscopic zones of coagulated tissue that heal over several weeks while the skin appears normal.

Table 1. Classification of wrinkles and degree of elastosis³

Class	Wrinkling	Score	Degree of Elastosis
I	Fine wrinkles (rhytides)	1-3	Mild (fine textural changes with subtly accentuated skin lines)
II	Fine to moderate depth wrinkles, moderate number of lines	4-6	Moderate (distinct papular elastosis [individual papules with yellow translucency under direct lighting] and dyschromia)
III	Fine to deep wrinkles, numerous lines, with or without redundant skin folds	7-9	Severe (multipapular and confluent elastosis [thickened yellow and pallid] approaching or consistent with cutis rhomboidalis)

MATERIALS AND METHODS

For this prospective, split-face study, 10 Caucasian subjects (9 women) with visible evidence of cutaneous photodamage were selected for participation. All subjects were given a physical examination and their medical histories were reviewed. Subjects applied sunscreen daily for at least two weeks before study began. They were instructed to avoid sun exposure and to apply broad-spectrum sunscreen (at least 30 SPF) daily during the study period.

For each subject, one side of the face was treated with the CO₂ device and the other side was treated with the Fraxel SR™ device. The sides of the face were randomized to one of the two devices at a ratio of 1:1. All subjects provided signed informed consent to participation.

For the ActiveFX-treated facial side, topical anesthetic was applied before treatment and oral pain medication was given as needed. For the Fraxel SR™-treated side, blue dye (OptiGuide Blue) was applied and allowed to dry. Lidocaine (1%) was injected before treatment and oral pain medication given as needed. The side of the face randomized to receive Fraxel SR™ treatment received five treatments at two-week intervals and the ActiveFX-treated side received a single treatment during the visit for the final Fraxel SR™ treatment. The ActiveFX treatment parameters were 90 to 100 mJ of energy with a density of 3 (82% ablation) and pattern generation ranging from 75 to 100 Hz. Only a single pass was made. For the Fraxel SR™, the first treatment started at 8 mJ at 250 density for 8 passes. If secondary spot treatment was needed for difficult areas, two

additional passes were made at 10 mJ and 125 to 250 density settings. For the second through the fifth treatments, energy was increased gradually to a maximum of 18 mJ at 250 density for a total of 8 passes. For secondary spot treatment of difficult areas, settings were 10 to 18 mJ at 125 density; 2 additional (for a total of 10) passes were made for periorbital areas at 10 to 18 mJ and 125 density; and 3 to 4 additional passes were made for the perioral areas, forehead, cheeks, and labial folds. After treatment the blue dye was removed with gentle facial cleanser and water.

After treatment with the ActiveFX-treated facial side, subjects were instructed to (1) maintain a barrier coating of occlusive ointment to prevent direct contact between the treated tissue and air during healing and (2) wash the treated area with cool water, vinegar, or Cetaphil at least 4 times daily for five days. For the Fraxel SR™-treated side, subjects were instructed to apply UVA/UVB sunscreen with an SPF at least 30 and containing a physical sun block, apply bland moisturizers to relieve itching and dryness, and, at the investigator's discretion, to use ice packs or pain medication.

Subjects were asked to evaluate the downtime after each treatment and to return 3 months and 6 months after the final treatment for follow-up evaluation.

Images of both sides of the face of each participant were obtained by digital photography (Model S2PRO, Fuji Finepix digital camera and Canfield Mirror Suite software) at all visits before treatment and at each follow-up visit. The same settings for exposure, lighting, flash, and focal length were used for each photograph. Subjects were positioned at the

same angles and distances from the camera for each photograph. Skin was cleansed thoroughly before photography.

From each of at least three subjects, four biopsy specimens were obtained from each side of the face: one before each treatment, one immediately after each treatment, and one at 3 months and at 6 months after the final treatment. Eight biopsy specimens were obtained from each of the three subjects. Histological analysis of each specimen was conducted according to standard procedures for light or electron microscopy.

Baseline and posttreatment evaluations were compared by the Wilcoxon Signed Rank test and results of the two devices were compared by the Mann Whitney test (non-paired results). All statistical tests were two-sided.

RESULTS AND DISCUSSION

Eight women and 1 man, aged 49.9 ± 8.5 years; skin types I (n=1), II (n=2), III (n=6), and IV (n=1), and Elastosis Score 2 (n=7), 4 (n=1), or not available (n=2), completed the study.

The immediate response after each treatment with both devices was the appearance of erythema. For the Fraxel SR™ treatment, severity was moderate in most treated areas and after each treatment session. For the ActiveFX treatment, severity was moderate in all treated areas.

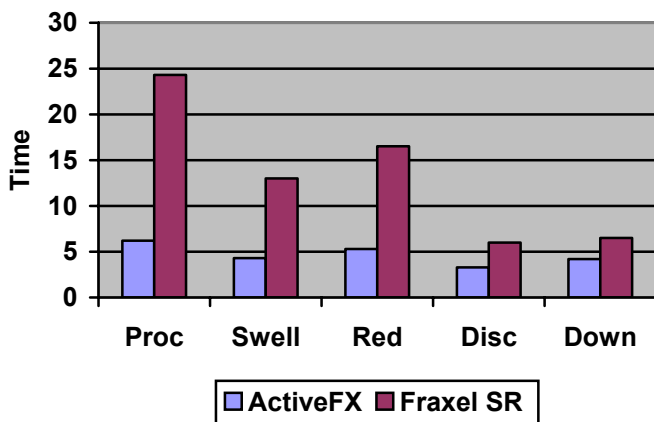


Figure 1. Mean times for procedure (Proc), swelling (Swell), redness (Red), discomfort (Disc), and downtime (Down) for the fractional ablative CO₂ device (ActiveFX) and the fractional photothermolytic nonablative device (Fraxel SR™).

All times are expressed in days except procedure time, which is in minutes. Procedure time is for a single session of either device. In all cases the time was less for the ActiveFX device.

The comparative results are shown in Figure 1. The treatment duration with ActiveFX was 6.2 minutes compared to the mean of 24.3 minutes with the Fraxel SR™; the difference was statistically significant ($p = 0.0002$). The swelling after a single CO₂ treatment resolved within 4.3 days with ActiveFX vs. a total of 13.0 days for the five Fraxel SR™ treatments; posttreatment redness resolved in 5.3 days with the ActiveFX compared to a mean of 16.5 days (5 treatments) with the Fraxel SR™; duration of posttreatment discomfort was 3.3 days with the ActiveFX compared to a mean of 6.0 days (5 treatments) with the Fraxel SR™; and the downtime was 4.2 days with the ActiveFX compared to a mean of 6.5 days (5 treatments) with the Fraxel SR™.

For clinical improvement, the investigator and subject assessments at 3 months and 6 months did not differ significantly between the investigator and subjects. A clinical example is shown in Figure 2.

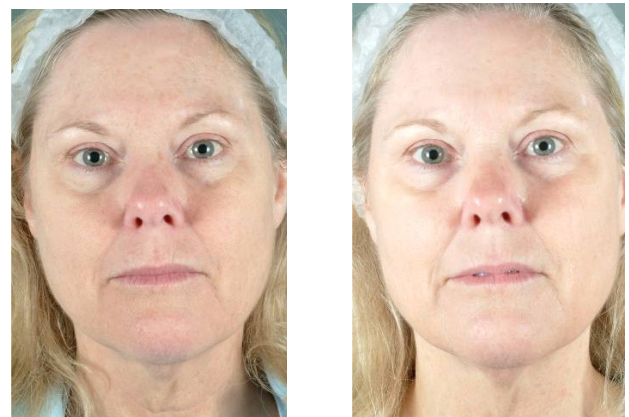

Figure 2. The left photograph shows the subject before treatment and the right photograph shows the subject after a single ActiveFX treatment with the fractional ablative CO₂ device (subject's left side) and after five Fraxel SR™ treatments with the fractional nonablative laser device (subject's right side). The ActiveFX settings were 100 mJ, 100 Hz, pattern 3 (square), spot size 7 mm, and density 3. A single pass was made. The Fraxel SR™ settings were increased with each treatment on the basis of the patient's response. Energy levels were 8 – 16 mJ and densities were at 125 to 250. Eight passes were made at each session. Two additional passes were made on "problem" areas; peri-orbital and nasal labial folds were treated at 2 mJ higher than treatment energy.

levels (10-18 mJ) and densities were reduced to 125 if necessary. Photograph courtesy of James A. Heinrich, M.D.

Subject satisfaction at 3 months and at 6 months did not differ significantly between the two devices.

Histological studies showed that collagen stimulation was 50% greater with the ActiveFX device. The results for one subject are shown in Figure 3.

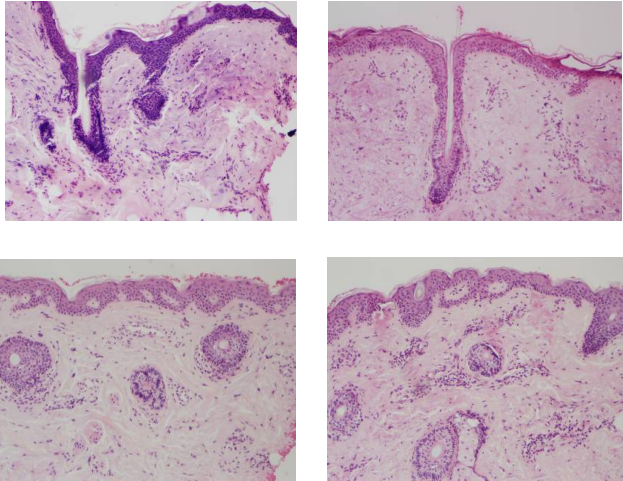


Figure 3. Histology slides of biopsy sections taken before treatment (left) and 6 months after the final treatment (right). The subject received a single ActiveFX treatment with the fractional ablative CO₂ device on one facial side (top) and five Fraxel SR™ treatments with the fractional nonablative laser device (bottom) on the other facial side. Micrographic analysis showed a 30% increase in new collagen on the CO₂-treated side and a 15% increase of new collagen on the the nonablative-treated side. Slides were evaluated by pathologists Justin H. Ekuon, M.D., and Alireza Tafazzoli, M.D. Photographs courtesy of James A. Heinrich, M.D.

CONCLUSIONS

- A single pass, single treatment with ActiveFX provided 50% more collagen stimulation than five, multi-pass Fraxel SR treatments.
- A single pass, single treatment with ActiveFX provided superior rhytid and histological results as compared to five multi-pass Fraxel SR treatments.
- One ActiveFX treatment results in less total downtime than five Fraxel SR treatments.

- While not a part of this study, the economics of ActiveFX vs Fraxel SR treatment should be noted. A single pass, single treatment with ActiveFX takes less time to perform, costs less for the subject, and has no recurring disposable cost.

REFERENCES

1. Railan D, Kilmer S. Ablative treatment of photoaging. *Dermatologic Therapy*, Vol.18, 2005, 227-241.
2. 510(k) Summary.
<http://www.fda.gov/cdrh/pdf5/K050841.pdf>:
Accessed October 14, 2007.
3. Fitzpatrick R, Geronemus R, Goldberg D, Kaminer M, Kilmer S, Ruiz-Esparza J. Multicenter study of noninvasive radiofrequency for periorbital tissue tightening. *Lasers Surg Med* 2003;33(4):232-42