

EFFECTIVE TREATMENT OF TRAUMATIC TATTOO WITH SILKPEEL™ DERMALINFUSION DURING ISOTRETINOIN TREATMENT

*Adam Wray, DO, Dan Marshall, DO, Lloyd Cleaver, DO, FAOCD
Northeast Regional Medical Center
Kirksville, MO*

ABSTRACT

BACKGROUND. Managing patients with traumatic tattooing can be challenging. Immediate removal of particles provides the best cosmetic outcome while delayed treatment makes the case more difficult to manage. Most treatment modalities are contraindicated in patients on isotretinoin. SilkPeel™ DermalInfusion is a useful alternative, particularly with patients on isotretinoin.

METHODS. We report a new case of explosive traumatic tattoo in an adolescent on isotretinoin for several months prior to the explosion successfully treated with SilkPeel DermalInfusion using saline irrigation at three day and two week intervals with the first treatment performed within 72 hours after the accident. Adjunctive treatment with comedone extractors and Vigilon were used as well.

RESULTS. Most of the lesions were removed with excellent cosmetic results and no scarring.

CONCLUSION. To our knowledge, this is the first reported case of successful treatment of traumatic tattoo with dermalinfusion during isotretinoin therapy. SilkPeel™ DermalInfusion is a useful treatment modality for managing traumatic tattoo during isotretinoin therapy.

INTRODUCTION

Traumatic tattoos occur from a variety of circumstances including motor vehicle accidents, falls, and explosions from fireworks or firearms. The particulate embedded in the skin can include carbon particles, gunpowder, dust, and asphalt. If left untreated, these lesions can lead to permanent disfigurement and social stigmata. Reports show some patients avoiding public places and activities as well as stopped working.¹

Treatment of the traumatic tattoo is complicated with isotretinoin therapy. Several reports show increased risk of keloid formation and scarring patients treated with dermabrasion or laser therapy.^{2 3 4 5} Yet, cosmesis is enhanced if lesions are treated immediately.⁶ The best treatment modality would be one that could be done immediately, is effective, and has minimal morbidity.

CASE REPORT

A 16 year old white male presented with traumatic tattoos from an explosion 24 hours prior to presentation. He was using a cutting torch to remove a fuel tank that was presumed empty from a leak. There was a small amount of fuel and the tank exploded blasting carbon particles, undercoating, and tar injuring the patients face and hands. Luckily, there was no injury to the orbits. He was initially evaluated in the E.R. where the areas were scrubbed with soap and water. Because the particulate was not able to be completely removed, he was referred to our clinic the next day. His medical history was significant for nodulocystic acne with several months treatment of Accutane

Physical exam revealed a well developed, well nourished 16 year old white male with extensive traumatic tattooing of the face, ears, and hands. The tattooing was especially intense around the upper and lower eyelids. In addition, the exam revealed significant 1st degree burn of the face including the forehead and helices of both ears.

Following extensive discussion and treatment options, SilkPeel™ DermalInfusion was chosen with saline irrigation. This was performed 48 hours after the accident and repeated at day 3 and again at day 12. Each treatment consisted of multiple passes with the SilkPeel™ DermalInfusion as well as the use of comedone extractors for deeper lesions. Vigilon was applied to the forehead and cheeks following each session and instructed to apply every night. Bactroban ointment was prescribed BID as well as polysporin ophthalmic ointment BID to eyelids. Greater than 50% of the particulate was removed after the first treatment with improvement after each visit. At one and two month follow ups the patient was noted to have significant improvement of his traumatic tattooing with excellent cosmesis and no complications.

DISCUSSION

The management of traumatic tattoos has been a difficult problem that has been reported on since World War I.⁷ Iverson⁸ began using dermabrasion in World War II with ordinary sandpaper wrapped around a gauze roll. Later he started using waterproof emery paper to avoid shedding of particulate back into the wound. Dermabrasion is best when used within 72 hours of the accident.⁶ When the tattoo is left untreated for a long time, the mini punch technique is useful. Since then other treatment strategies have been used including microsurgical excision, salabrasion, phenol, cryosurgery, electrosurgery, and Q-switched lasers.⁹

Laser therapy is popular for treatment of traumatic tattoos because of the lower risk of scarring. The most popular lasers used are the Q-switched ruby, Q-switched Nd:YAG, and Q-switched alexandrite lasers. Historically, the carbon dioxide as well as the argon laser have been used as well. While the more selective Q-switched lasers reduce risk of scarring, the nanosecond pulse duration restricts treatment to particles of 10-40 cubic microns.¹⁰ Although scarring is reduced with the selective lasers, they are not without other complications such as generalized dermatitis, urticaria, hypopigmentation, delayed scarring and keloid formation, hyperpigmentation, delayed healing, acne and milia, infections, ectropion, pruritus, and pain.¹¹ Rheingold et al reported a compartment syndrome of the upper extremity following treatment of a 6 cm

tattoo on the dorsal right forearm following treatment with a Q-switched Nd:YAG laser.¹² Fusade et al reported poxlike scars from microexplosion of gunpowder particulate embedded in the skin of several patients treated with Q-switched Nd:YAG laser therapy.¹³ Granulomatous reactions have been observed as well status post laser therapy.¹⁴

The most common sites of injury for traumatic tattoo are the face, hands, and eyes. Male children are the primary victims of explosive traumatic tattoos. The majority of patients present with severe burns as well.⁹ However, in this case the patient only had 1st degree burns although somewhat extensive. This case was complicated by the patient being on isotretinoin therapy.

Isotretinoin has an obvious suppressive effect on sebaceous gland size and activity.⁴ Because the pilosebaceous unit is integral to re-epithelialization, wound healing can be delayed or even altered while on isotretinoin. Collagenase, the enzyme involved in degradation of collagen, can be markedly reduced in both normal¹⁵ and keloid skin¹⁶ with retinoids. If collagenase is suppressed, then collagen accumulation, hypertrophic scarring, and keloid formation can occur.⁵ This is especially evident in patients surgically treated while on isotretinoin.

CONCLUSION

Treatment of traumatic tattoo is difficult at best, especially when complicated with isotretinoin therapy. We report the first case to our knowledge of successful treatment of traumatic tattooing with SilkPeel™ DermalInfusion using saline irrigation during isotretinoin therapy.

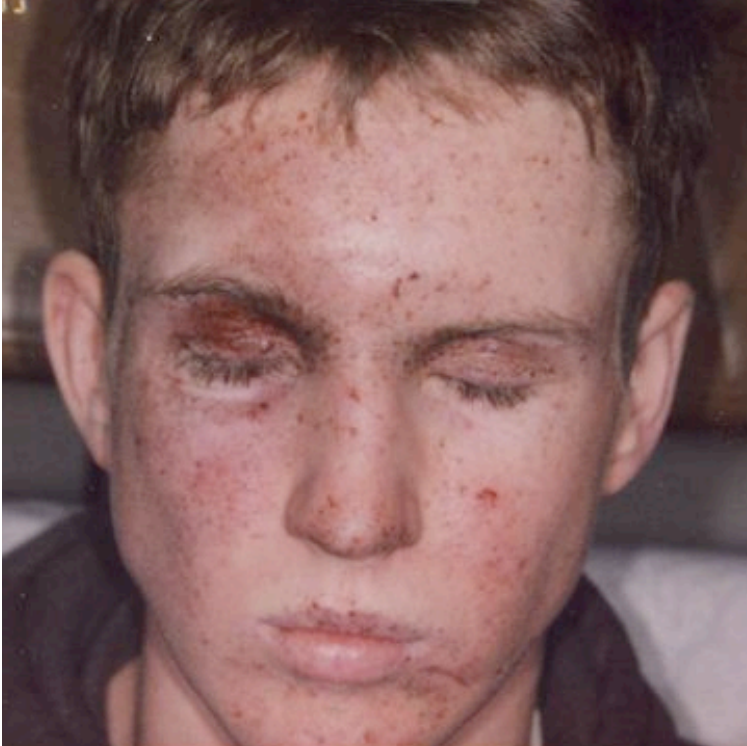

Figure 1- Presentation prior to first SilkPeel™ DermalInfusion

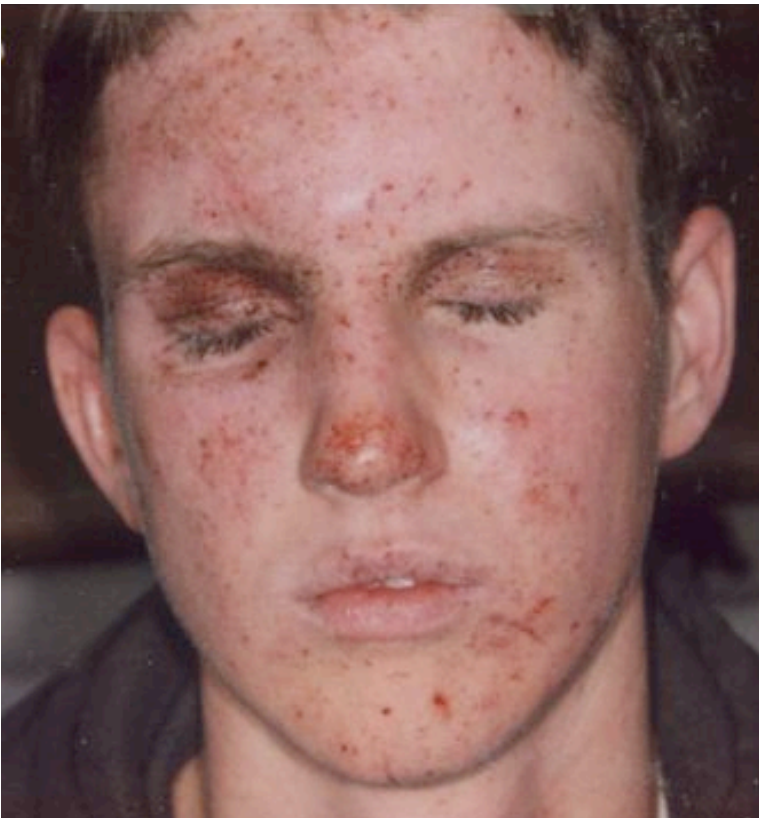

Figure 2- Presentation immediately after first SilkPeel™ DermalInfusion

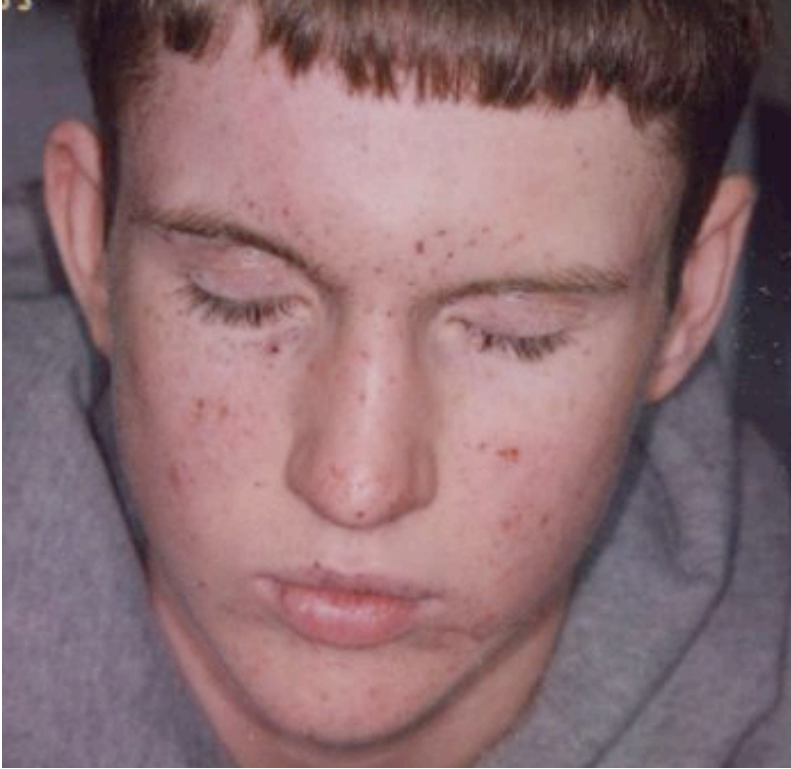

Figure 3- 3 days later after 2nd treatment

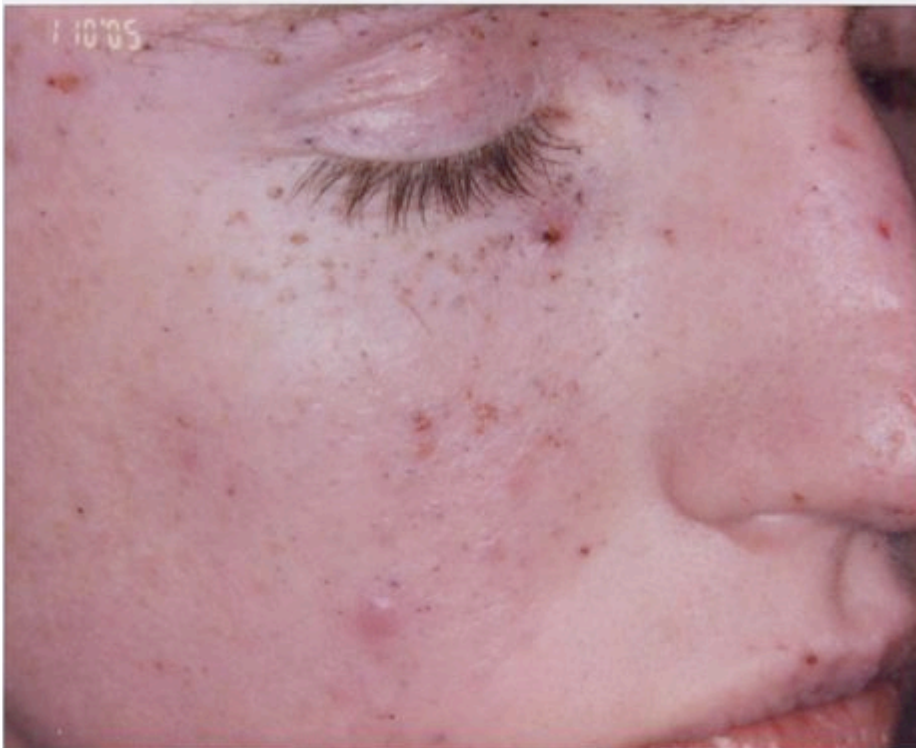

Figure 4- 3 days later after 2nd treatment

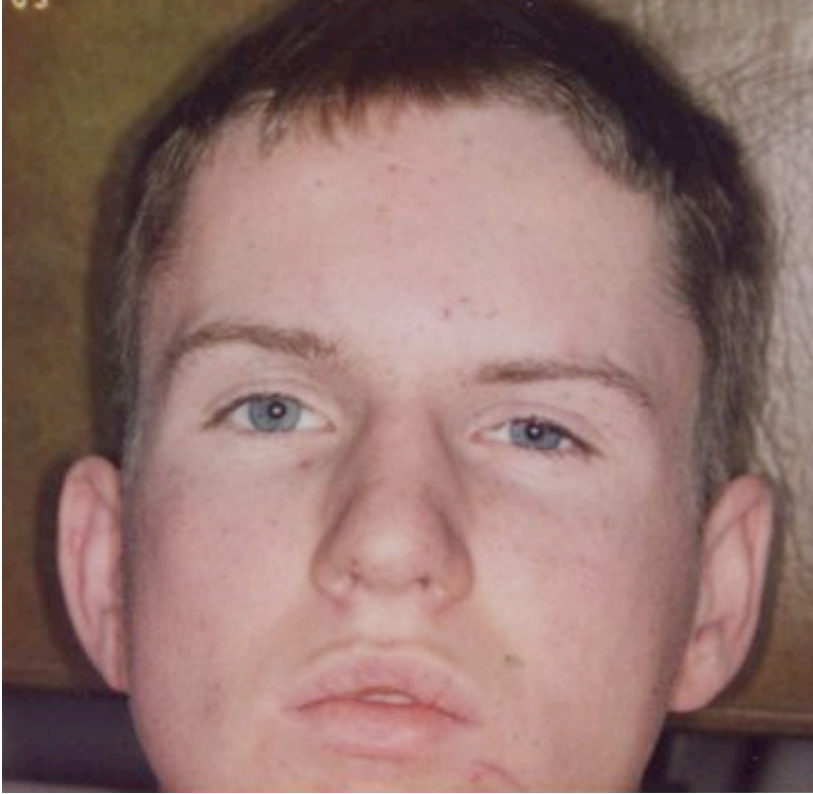

Figure 5- 12 days later after 3rd treatment

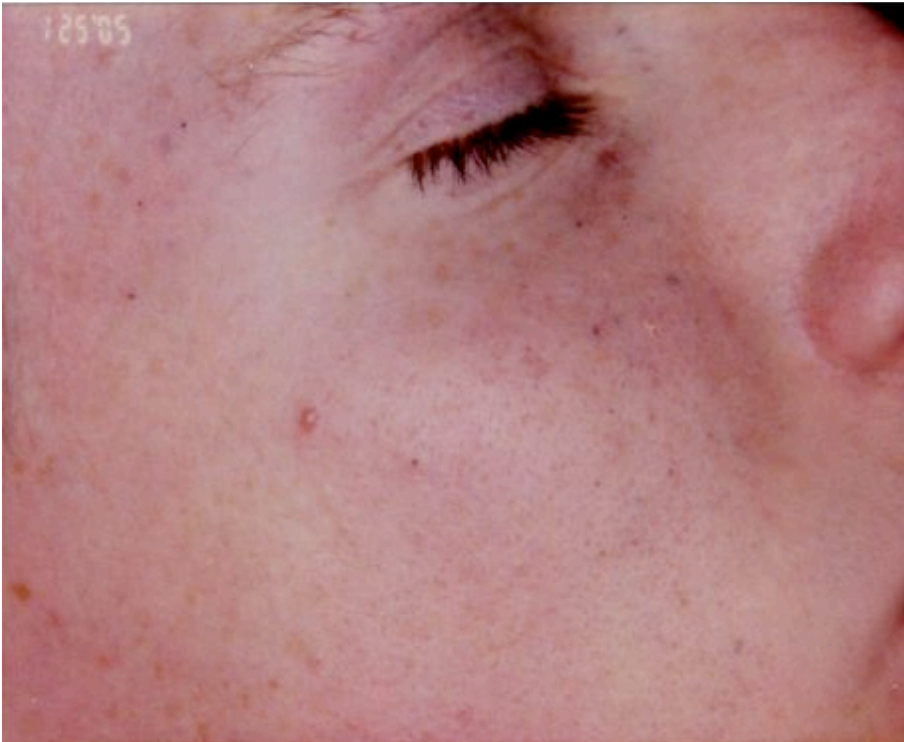


Figure 6- 12 days later after 3rd treatment

-
- ¹ Sun Boashan, Guan Wenxiang, *Treating traumatic tattoo by micro-incision*, Chinese Medical Journal 2000; 113, 7: 670-671
- ² William P. Coleman III, *Dermabrasion and Hypertrophic Scars*, Int J Dermatol 1991; 30, 9: 629-631
- ³ H. Zacariae, *Delayed wound healing and keloid formation following argon laser treatment or dermabrasion during isotretinoin treatment*, Br J Dermatol. 1988; 118, 5: 703-706
- ⁴ Richard Rubentsein, HH Roenigk Jr., SJ Stegman, W. Hanke, *Atypical keloids after dermabrasion of patients taking isotretinoin*, J Am Acad Dermatol. 1986; 15, 2: 280-285
- ⁵ Bruce E. Katz, DF MacFarlane, *Atypical facial scarring after isotretinoin therapy in a patient with previous dermabrasion*, J Am Acad Dermatol. 1994; 30, 5: 852-853
- ⁶ N. Pallua, W. Schneider, A. Berger, *Treatment of traumatic facial tattoos caused by black gunpowder*, Injury 1993; 24, 4: 227-230
- ⁷ H.C. Lindsay, *Removal of powder tattoo by minor surgery*, JAMA 1937; 109: 1530
- ⁸ Robert Parsons, *The management of traumatic tattoos*, Clinics in Plastic Surgery 1975; 2, 4: 517-522
- ⁹ Fouad El Sayed, A. Ammouy, R. Dhaybi, *Treatment of fireworks tattoos with the Q-switched ruby laser*, Dermatol. Surg. 2005; 31, 6: 706-708
- ¹⁰ K. Kunzi-Rapp, GM Krahn, S. Wortman, R-U Peter, *Early treatment of traumatic tattoo by erbium-YAG laser*, Br J Dermatol. 2001; 144: 219-221
- ¹¹ Elizabeth I. McBurney, *Side effects and complications of laser therapy*, Dermatology Clinics 2002; 20, 1: 165-176
- ¹² LM Rheingold, MC Fater, EH Courtiss, *Compartment syndrome of the upper extremity following cutaneous laser surgery*, Plast Reconstr Surg 1997; 99: 1418-1420
- ¹³ T. Fusade, G. Toubel, C. Grogard, JM Mazer, *Treatment of gunpowder traumatic tattoo by Q-switched Nd:YAG laser: an unusual adverse effect*, Dermatol. Surg. 2000; 26:1057-1059
- ¹⁴ Suzanne L Kilmer, *Laser eradication of pigmented lesions and tattoos*, Dermatologic Clinics 2002; 20, 1: 37-53
- ¹⁵ EA Baur, JL Steltzer, AZ Eisen, *Inhibition of collagen degradative enzymes by retinoic acid in vitro*, J Am Acad Dermatol 1982; 6: 603-607
- ¹⁶ RP Abergel, CA Meeker, H Oikarinen, et al, *Retinoid modulation of connective tissue metabolism in keloid fibroblast cultures*, Arch Dermatol 1985; 121: 632-635