

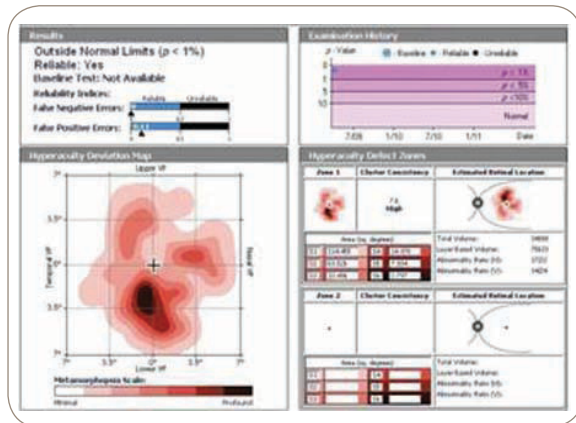
## CASE STUDY | TREATMENT MONITORING WITH PHP

Mohammad Rafeetary, O.D. — Charles Retina Institute, Memphis, TN

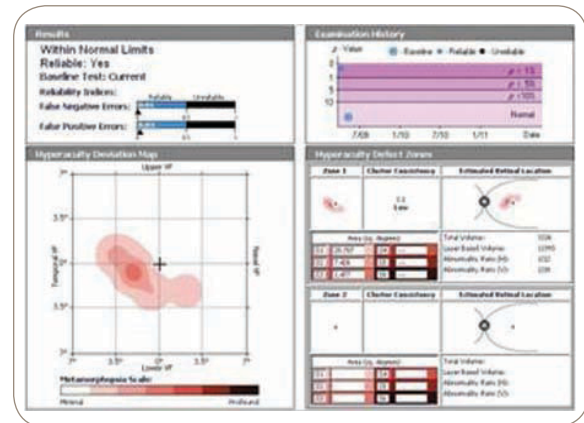
PHP may be a better indicator of actual visual function than Snellen visual acuity in many cases. This 32-year-old white male has a history of ocular histoplasmosis and choroidal neovascular membrane. He previously had a successful intravitreal Avastin (IVA) injection, and returned with a subsequent recurrence, at which time his vision was 20/40<sup>-2</sup>.

Following repeated IVA, he returned showing good response and regression of the CNV. However, in spite of the patient's subjective visual improvement, the patient's Snellen visual acuity actually measured 20/50. The noted decrease in metamorphopsia on the PHP correlates with the patient's subjective visual improvement.

### PHP

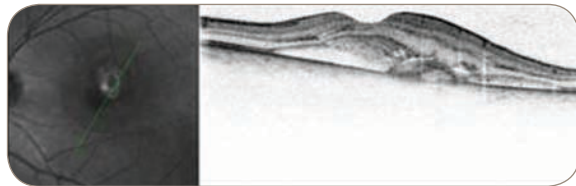


Abnormal response.



Findings show improvement of the condition.

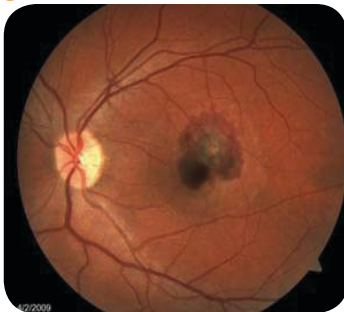### OCT



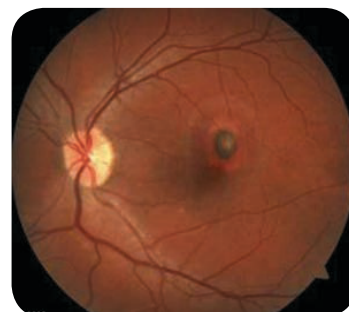Juxtafoveal membrane. Subretinal fluid.



### FUNDUS PHOTO



Macular Hemorrhage



Foresee PHP manufactured by Notal Vision, Ltd.