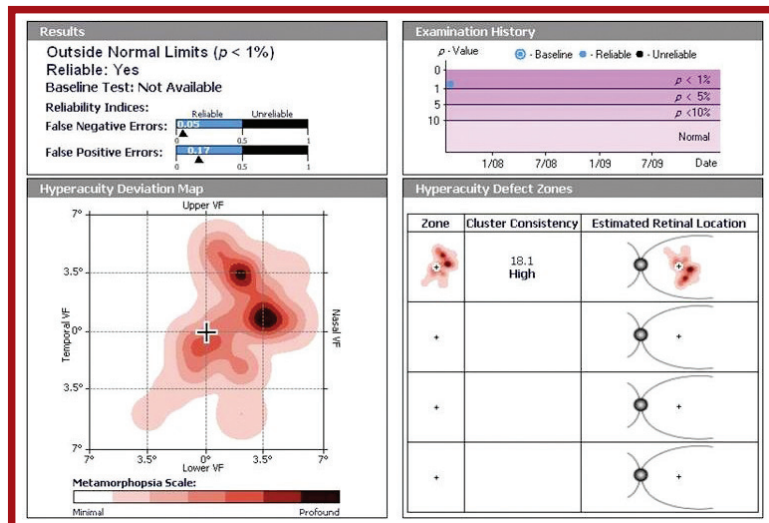


Case Study

Dr. P. Garfinkle, Ohio, US

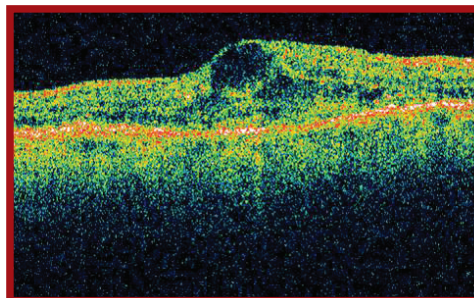
Case Description:

81 year old female presented with vague complaints of vision loss but with no clinical evidence of CNV present. "The PHP enhanced my decision making and caused me to seek additional testing. The positive PHP test, indicating the possible presence of CNV, was confirmed by the OCT and FA, resulting in prompt treatment and restored vision. Without the early detection of the PHP, this patient may have developed profound vision loss."



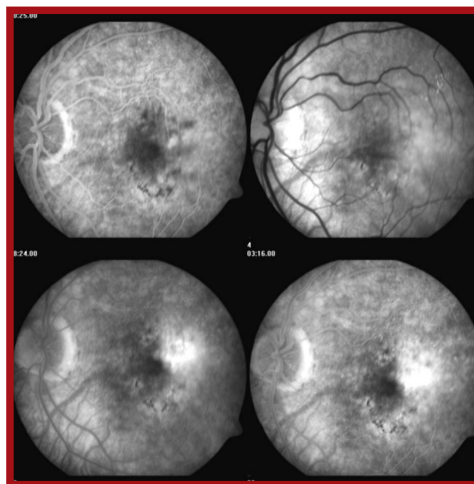
Abnormal test indicates a high probability of neovascular AMD. Aug. 2007

PHP



Significant macular edema with increased foveal thickness seen on OCT. Aug. 2007

OCT



FA showed leakage consistent with neovascular AMD. Aug. 2007

FA